

## White piedra—a case report and review of the literature

HOWARD K. STEINMAN\* AND ROBERT B. PAPPENFORT†

\**St John's Hospital for Diseases of the Skin, 5 Lisle Street, Leicester Square, London WC2H 7BJ*  
and †*University of California, San Diego School of Medicine, U.S.A.*

*Accepted for publication 21 June 1984*

### Summary

White piedra (trichosporosis) is an unusual fungal infection of hair characterised by the presence of numerous, discrete, soft, asymptomatic nodules attached to the infected hair shafts. It may occur on the scalp, eyebrows, eyelashes, beard, axilla, or in the groin (Smith, Murtishaw & McBride, 1973; Taplin & Rebell, 1979a), although most infections occur on the face or scalp (Smith *et al.*, 1973). Caused by the yeast-like fungus *Trichosporon beigeli*, white piedra was first described in London (Beigel, 1865), and has since been reported in Europe, North and South America, and Asia (Scott, 1951; Benson, Lapins & Odom, 1983). Successful treatment of white piedra has been achieved with simple hair clipping and with the use of various topical medications. To our knowledge, there have been no reports of successful treatment with the use of topically applied imidazole preparations. We report a case of white piedra confined to the scrotum that responded to topical clotrimazole lotion.

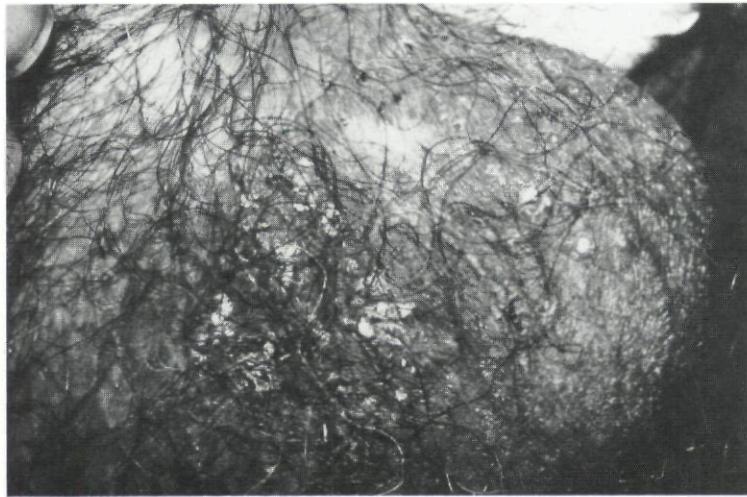### Case report

The patient was a 53-year-old Caucasian man who complained of an asymptomatic 'rash' on his scrotal hairs. He had no prior history of any similar disorder but had acquired a chronic fungal infection of his left hand and both feet in 1950. No scrotal skin or hair abnormalities had been present 5 months prior to presentation when he was treated at our hospital for a testicular bacterial abscess with incision and drainage and systemic antibiotic therapy.

Physical examination revealed the presence of many abnormal scrotal hairs on which there

Correspondence: Dr Steinman.

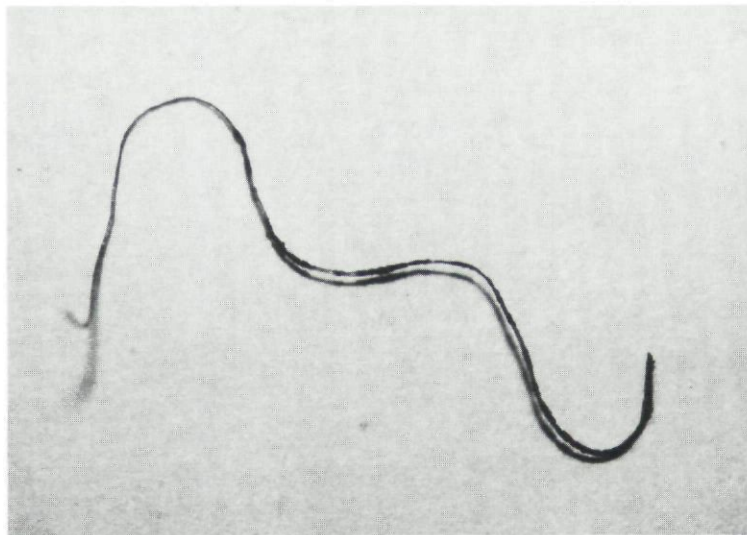
\*Clinical and laboratory data were obtained while Dr. Steinman was a resident in dermatology, Division of Dermatology, University of California, San Diego School of Medicine, U.S.A.



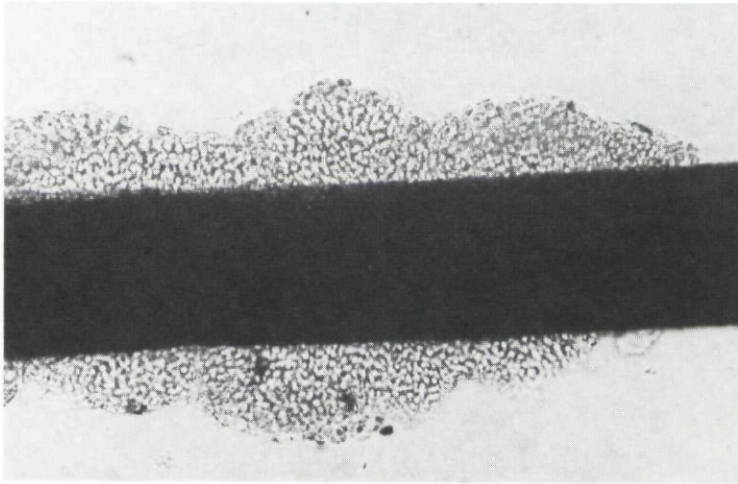
**Figure 1.** Scrotal hairs showing typical nodules of white piedra.

were one to several yellow-brown, soft, loosely adherent, superficial concretions that felt gritty on palpation (Fig. 1, 2). Scalp, eyebrow, eyelash, axillary, and body hairs were normal. There was no evidence of poor personal hygiene. The left palm and both soles showed areas of faint erythema and scaling. There were also signs of seborrheic dermatitis of the scalp and numerous solar keratoses of the forehead, dorsal hands, and forearms.

A 10% potassium hydroxide mount of an infected scrotal hair viewed under the microscope at 400 magnification showed that the concretions were composed of numerous arthrospores in compact masses encasing the hair shaft (Fig. 3). Potassium hydroxide preparation of skin scrapings from his left palm and both soles revealed hyphal elements typical of a dermatophyte.



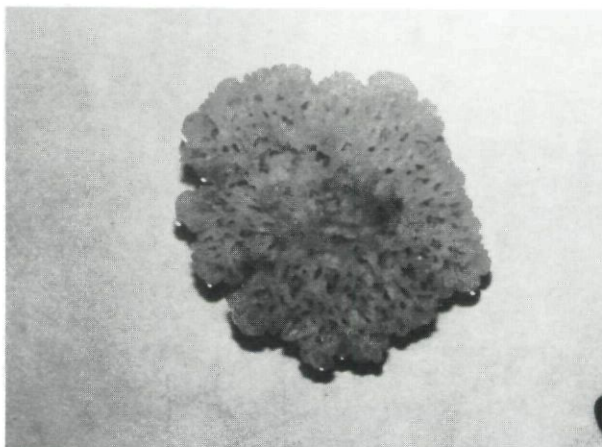
**Figure 2.** An infected scrotal hair showing the presence of multiple nodules on the hair shaft.



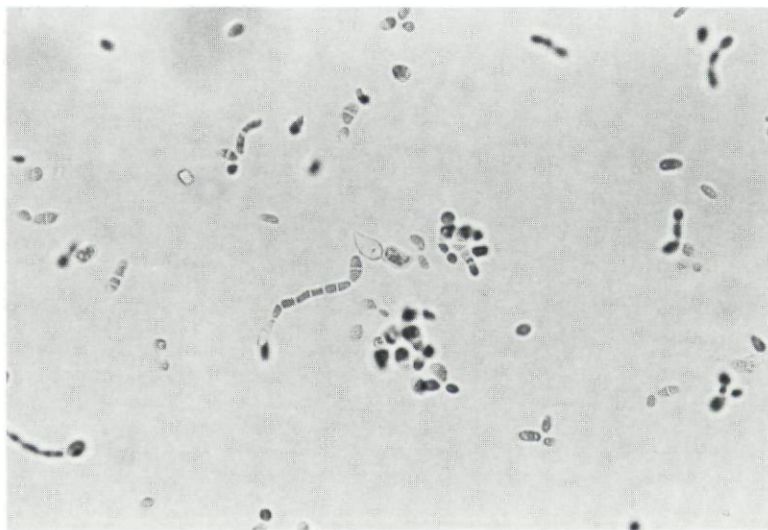
**Figure 3.** Photomicrograph of a hair nodule showing arthrospores growing perpendicular to the hair shaft (potassium hydroxide mount; original magnification,  $\times 150$ ).

An infected scrotal hair and skin scrapings from the palm and soles were obtained for fungal culture, placed on dermatophyte test medium (DTM) and stored at room temperature. Within 1 week the scrotal hair culture showed mucoid growth. Subsequent cultural and biochemical tests and microscopic examination of the organism (Fig. 4, 5) performed by the Mycology Laboratory of the United States Veterans' Administration Hospital, San Diego, U.S.A. confirmed that the fungus was *Trichosporon beigelii*. Cultures from left palm and sole grew *Trichophyton rubrum*.

The patient applied clotrimazole lotion to his scrotum, palms, and soles three times daily for 21 days without removing infected scrotal hairs. This eradicated the *T. beigelii* infection but caused no improvement of the *tinea pedis et manum*. Clotrimazole lotion was discontinued and the patient was given oral griseofulvin, 250 mg three times daily, which resulted in clearance of



**Figure 4.** Mature culture of *Trichosporon beigelii* on Sabouraud's agar showing multiple folds and radial furrows.



**Figure 5.** Photomicrograph of *Trichosporon beigeli* showing arthrospores and budding yeasts (original magnification,  $\times 360$ ).

the dermatophyte infection after an additional 21 days. The patient continued to take griseofulvin, and 9 months from his initial presentation his scrotum remained free of disease, although there was a recurrence of his *tinea pedis et manum* after 6 months of therapy.

## Discussion

There are two distinct, unrelated forms of piedra. These are white piedra, caused by *T. beigeli* and black piedra, caused by *Piedraia hortai*. Both are fungal infections confined to the hair shaft, sparing adjacent skin. The term 'piedra', a Spanish word meaning 'stone', was initially used to describe the hard nodules of black piedra (as opposed to the softer nodules of white piedra) which may generate a sound similar to pebbles rattling in a bean bag when struck by the teeth of a comb (Smith *et al.*, 1973). Some authors prefer the name 'trichosporosis' for the hair infection caused by *T. beigeli* to clearly distinguish it from black piedra (Taplin & Rebell, 1979a).

Black piedra manifests as numerous, hard, brown to black hair nodules that are usually confined to the scalp. The nodules are firmer and more adherent than those of white piedra and do not alter the tensile strength of the hairs (Taplin & Rebell, 1979b). Black piedra is prevalent in tropical climates in South-east Asia, Malaysia, the West Indies, and South and Central America where the fungus is a parasite on certain tree leaves (Benson *et al.*, 1983) and where it infects wild primates as well as man (Taplin & Rebell, 1979b). The nodules are composed of masses of brown to black fungus cells called asci. Each asci is about 25  $\mu\text{m}$  long and contains eight fusiform, single-celled ascospores (Taplin & Rebell, 1979b). The fungus can be cultured on Sabouraud's agar and growth is not inhibited by cycloheximide (Benson *et al.*, 1983).

White piedra was first described by Beigel (1865) when he noted the characteristic nodules on false hair buns and named the condition 'chignon fungus' (Taplin & Rebell, 1979a). The causative organism was named *Pleurococcus beigeli* by Rabenhurst in 1867 (Taplin & Rebell, 1979a; McGinnis 1980), and the name was changed to *T. beigeli* by Vuillemin in 1902. *T. beigeli*

is the same organism as the saprophyte *T. cutaneum* described by de Beurman and Gougerot, and recent published reports concerning white piedra vary in their use of the name *T. beigelii* versus *T. cutaneum*. The name *T. beigelii* apparently has taxonomic priority (Taplin & Rebell, 1979a; McGinnis, 1980).

The nodules of white piedra vary in colour from white to brown-black or green, are visible to the naked eye, do not fluoresce under Wood's light, and feel gritty on palpation. They are soft and spongy, are easily removed from the hair (Benson *et al.*, 1983), and may vary in size from microscopic to 0.5 mm in diameter and up to 3 mm in length (Smith *et al.*, 1973) (Fig. 2). Nodules are often located on the distal end of the hair, and multiple nodules can be present on a single hair. The nodules consist of hyphae, arthrospores and infrequent blastospores that grow both into the hair and perpendicular to the hair surface (Fig. 3) (Taplin & Rebell, 1979a). Infection may start at a break in the hair cuticle, after which intrapilar growth can weaken the hair, causing the hair to break (Emmons *et al.*, 1979; Rippon, 1982). This may account for many of the nodular swellings being located at the distal end of the infected hairs.

Since first described in England, white piedra has been reported in Western and Central Europe, the United States, South America, and the Orient (Smith *et al.*, 1973). White piedra may involve the hairs of the scalp, mustache, beard, eyelashes, eyebrows, axilla, or groin (Scott, 1951; Smith *et al.*, 1973; Taplin & Rebell, 1979a). In tropical climates it more commonly affects the scalp, while in temperate climates, the moustache, beard, and pubic hair are more commonly infected (Taplin & Rebell, 1979a). As with our patient, there have been numerous previous reports of infection confined to the scrotum (Patterson, Laine & Taylor, 1962; Londero, Ramos & Fischman, 1966; Kotovirta, Stubb & Salonen, 1975; Smith *et al.*, 1973; Fischman, Pires De Camargo & Meireles, 1980; Benson *et al.*, 1983). Our patient was also noted to have a *Trichophyton rubrum* infection of his left hand and both feet. There have been previous reports of a coexistent infection with *Trichophyton mentagrophytes* and *T. beigelii* on the inguinal skin and of a *Trichophyton rubrum* infection of the toe webs associated with a *T. beigelii* infection of the scrotum (Smith *et al.*, 1973).

Unlike *P. hortai*, which naturally parasitises primates and man, *Trichosporon beigelii* is a common saprophyte that only incidentally infects humans (Taplin & Rebell, 1979a). Potential sources of infection are numerous. *T. beigelii* has been isolated from soil, air (Rippon, 1982), river and lake water, animal excreta and sewage (Lodder, 1971). Infection has been reported in horses, other domestic animals, and a spider monkey (Smith *et al.*, 1973; Rippon, 1982). It has also been found to colonise human skin (Manzella, Berman & Kukrika, 1982, Haupt *et al.*, 1983), sputum (Rippon, 1982, Haupt *et al.*, 1983), urinary and gastrointestinal tracts (Taplin & Rebell, 1979a, Haupt *et al.*, 1983), and has been regarded as a laboratory contaminant (Evans *et al.*, 1980). Poor personal hygiene, diabetes (Taplin & Rebell, 1979a), and swimming in contaminated water (Rippon, 1982) are said to be predisposing factors in infection.

*Trichosporon beigelii* is an imperfect (asexual) yeast which belongs to the subfamily Trichosporoidae in the family Cryptococcaceae. It grows rapidly on Sabouraud's agar or DTM (Benson *et al.*, 1983) but, unlike *P. hortai*, it is inhibited by cycloheximide, which is present in mycologic selective media. It forms cream-coloured, yeast-like colonies that develop wrinkles and radial furrows with age (Rippon, 1982) (Fig. 4). In culture, the hyphae of *T. beigelii* separate into oval to rectangular arthrospores, 2–4  $\mu\text{m}$  in diameter and up to 8  $\mu\text{m}$  in length (Lodder,

1971). Infrequent blastospores may also be present (Fig. 5). The organism resembles *Geotrichum* and *Candida* species. *T. beigelii*, however, possesses both arthrospores and blastospores, whereas *Geotrichum* lacks blastospores and *Candida* species lack arthrospores (Taplin & Rebell, 1979a). The organism hydrolyses urea and assimilates glucose, galactose, sucrose, maltose, lactose, cellobiose, and trehalose, but does not ferment carbohydrates. It does not utilise potassium nitrate, and arbutin is split (Rippon, 1982).

In addition to causing a benign infection of hair, *T. beigelii* has been reported in association with pseudoainhum of the toes (Kamakam & Thambiah, 1981). *T. beigelii* has also caused serious systemic infections, most commonly in immunosuppressed hosts. Disseminated *T. beigelii* infections have been reported in patients with acute and chronic leukemia (Rivera & Cangir, 1975; Evans *et al.*, 1980; Gold *et al.*, 1981; Jameson *et al.*, 1981; Yung *et al.*, 1981; Manzella *et al.*, 1982, Haupt *et al.*, 1983). A cutaneous eruption characterised by purpuric papules, papulovesicles, and centrally necrotic nodules was observed in some of these patients from which the organism could be cultured (Yung *et al.*, 1981; Gold *et al.*, 1981; Manzella *et al.*, 1982). *T. beigelii* endocarditis has been reported following intravenous drug abuse (Brahn & Leonard, 1982), and aortic and mitral valve replacement (Madhaven, Eisses & Quinn, 1976; Marier *et al.*, 1978). Endophthalmitis has been reported following cataract extraction (Sheikh, Mahgoub & Bedi, 1974), and a *T. beigelii* brain abscess was noted in a patient with metastatic bronchial adenocarcinoma (Watson & Kallichurum, 1970). *T. beigelii* septicaemia has been reported in a kidney transplant patient (Madhaven *et al.*, 1976), and septicaemia and visceral infection has been reported in a patient receiving prednisone and azathioprine for chronic active hepatitis (Kirmani, Tauzon & Geelhoed, 1980). *T. beigelii* pneumonia has been reported in a kidney transplant patient and in a patient with multiple myeloma (Saul *et al.*, 1981).

White piedra must be distinguished from other hair infections, including black piedra and trichomycosis axillaris. Black piedra is distinguished by the greater hardness and adherence of the hair nodules and by its differing microscopic and culture morphology. The nodules of trichomycosis axillaris are more irregular in contour than those of white piedra, the hyphae are narrower (1  $\mu\text{m}$  as opposed to 2–4  $\mu\text{m}$  for *T. beigelii*), and the organism may fluoresce under Wood's light. Culture on Sabouraud's agar or DTM for *T. beigelii* and bacteriological media for corynebacterium will distinguish between the two diseases. Structural hair abnormalities, such as trichonodosis, monilethrix, and trichorrhexis nodosa, as well as hair casts, nits of pediculosis, hair dye and hair spray droplets, paint, glue, and dried genital secretions may simulate the nodular swellings of white piedra but can be easily distinguished from it by microscopic examination (Smith *et al.*, 1973; Taplin & Rebell, 1979b; Benson *et al.*, 1983).

Successful treatment of white piedra has been achieved with simple hair clipping and improvement of personal hygiene (Taplin & Rebell, 1979a). Topical treatment with Amphotericin B lotion (Smith *et al.*, 1973), solution of mercury bichloride (1:2000) (Scott, 1951), 5% ammoniated mercury ointment (Scott, 1951), and dequalinium chloride (Kamakam & Thambiah, 1981) are also effective. Benson *et al.* (1983) previously reported a case of scrotal white piedra treated with topical clotrimazole lotion. Twice daily application without removal of infected hairs failed to result in a clinical cure. Continued application after removal of involved hairs resulted in temporary resolution, but the disease recurred within 3 months of the cessation of therapy. Our patient applied clotrimazole lotion three times daily for 21 days

without hair removal, which resulted in clinical cure and no recurrence after 9 months of follow-up. However, the patient was also given systemic griseofulvin therapy for a coexistent dermatophyte infection after clotrimazole lotion was discontinued. Although it is conceivable that griseofulvin contributed to the eradication of the white piedra infection, this is unlikely. Griseofulvin is not effective in the treatment of infections caused by most yeasts (Roth, Sallman & Blank, 1959; Rippon, 1982), and no previous reports of *in vitro* sensitivity of *T. beigeli* to griseofulvin or of the use of griseofulvin in the treatment of cutaneous or systemic *T. beigeli* infections could be found. It is thus probable that treatment with clotrimazole lotion was responsible for the clinical cure in this patient.

### Acknowledgments

We wish to thank Miss Wendy Kaler for performing the laboratory identification of the fungi isolated from this patient and Dr Parviz Haghighi for providing the photomicrographs of *T. beigeli*.

### References

- BEIGEL, H. (1865) Cited by Langeron M. (1936) *Nouvelle Pratique Dermatologique*, **2**, 377.
- BENSON, P.M., LAPINS, N.A. & ODOM, R.B. (1983) White piedra. *Archives of Dermatology*, **119**, 602-604.
- BRAHN, E. & LEONARD, P.A. (1982) Trichosporon cutaneum endocarditis, sequela of intravenous drug abuse. *American Journal of Clinical Pathology*, **78**, 792-794.
- EMMONS, C.W., BINFORD, C.H., UTZ, J.P. & KWON-CHUNG, K.J. (1979) *Medical Mycology*, 3rd edition, p. 182. Lea & Febiger, Philadelphia.
- EVANS, H.L., KLETZEL, M., LAWSON, R.D., FRANKEL, L.S. & HOPFER, R.L. (1980) Systemic mycosis due to Trichosporon cutaneum. *Cancer*, **45**, 367-371.
- FISCHMAN, O., PIRES DE CAMARGO, Z. & MEIRELES, M.C.A. (1980) Genital white piedra: an emerging new fungal disease? *Proceedings of the Fifth International Conference on the Mycoses*. Superficial, cutaneous and subcutaneous infections. Caracas, Venezuela, 27-30 April, 1980.
- GOLD, J., POSTON, W., MERTELSMANN, R., LANGE, M., KIEHN, T., EDWARDS, F., BERNARD E., CHRISTIANSEN, K. & ARMSTRONG, D. (1981) Systemic infection with Trichosporon cutaneum in a patient with acute leukemia. *Cancer*, **48**, 2163-2167.
- HAUPT, H.M., MERZ, W.G., BESCHORNER, W.E., VAUGHN, W.P. & SARAL, R. (1983) Colonization and infection with Trichosporon species in the immunocompromised host. *Journal of Infectious Diseases*, **147**, 199-203.
- JAMESON, B., CARTER, R.L., WATSON, J.G. & HAY, R.J. (1981) An unexpected fungal infection in a patient with leukemia. *Journal of Clinical Pathology*, **34**, 267-270.
- KAMAKAM, A. & THAMBAIAH, A.S. (1981) Ainhum, trichosporosis, and Z-plasty. *Dermatologica*, **372**, 372-377.
- KIRMANI, N., TUAZON, C.U. & GEELHOED, G.W. (1980) Disseminated Trichosporon infection. *Archives of Internal Medicine*, **140**, 277-278.
- KOTOVIRTA, M., STUBB, S. & SALONEN, A. (1975) Trichosporosis (White piedra). *Acta Dermato-venereologica (Stockholm)*, **55**, 218-220.
- LODDER, J. (1971) *The Yeasts*, 2nd edition, p. 1317. Elsevier North Holland Inc, New York.
- LONDERO, A.T., RAMOS, C.D. & FISCHMAN, O. (1966) White piedra of unusual localization. *Sabouraudia*, **5**, 132-134.
- MADHAVEN, T., EISSES, J. & QUINN, E.L. (1976) Infection due to Trichosporon cutaneum, an uncommon systemic pathogen. *Henry Ford Hospital Medical Journal*, **24**, 27-30.

- MANZELLA, J.P., BERMAN, I.J. & KUKRIKA, M.D. (1982) Trichosporon beigeli fungemia and cutaneous dissemination. *Archives of Dermatology*, **118**, 343-345.
- MARIER, R., ZAKHIREH, B., DOWNS, J., WYNNE, B., HAMMOND, G.L. & ANDRIOLE, V.T. (1978) Trichosporon cutaneum endocarditis. *Scandinavian Journal of Infectious Disease*, **10**, 255-256.
- MCGINNIS, M.R. (1980) *Laboratory Handbook of Medical Mycology*, p. 399. Academic Press, New York.
- PATTERSON, J.C., LAINE, S.L. & TAYLOR, W.B. (1962) White piedra. *Archives of Dermatology*, **85**, 142-144.
- RIPPON, J.W., (1982) *Medical Mycology: The Pathogenic Fungi and The Pathogenic Actinomycetes*, 2nd edition, p. 148. 562 & 731. W.B. Saunders, Philadelphia.
- RIVERA, R. & CANGIR, A. (1975) Trichosporon sepsis and leukemia. *Cancer*, **36**, 1106-1110.
- ROTH, F.J., SALLMAN, B. & BLANK, H. (1959) In vitro studies of the antifungal antibiotic griseofulvin. *Journal of Investigative Dermatology*, **33**, 403-408.
- SAUL, S.H., KHACHATOORIAN, T., POORSATTAR, A., MYEROWITZ, R.L., GEYER, S.J., PASCULLE, A.W. & HO, M. (1981) Opportunistic Trichosporon pneumonia. *Archives of Pathology and Laboratory Medicine*, **105**, 456-459.
- SCOTT, M.J. (1951) Piedra. *Archives of Dermatology and Syphology*, **64**, 767.
- SHEIKH, H.A., MAHGOUN, S. & BEDI, K. (1974) Postoperative endophthalmitis due to Trichosporon cutaneum. *British Journal of Ophthalmology*, **58**, 591-594.
- SMITH, J.D., MURTISHAW, W.A. & MCBRIDE, M.E. (1973) White piedra (Trichosporosis). *Archives of Dermatology*, **107**, 439-442.
- TAPLIN, D. & REBELL, G. (1979a) Trichosporosis (White piedra). In: *Clinical Dermatology*. Vol. 3, Ch. 17.4. (Ed. by D.J.Dermis, R.L.Robson and J.M.McGuire). Harper & Row, Philadelphia.
- TAPLIN, D., REBELL, G. (1976b) Piedra (Black piedra). In: *Clinical Dermatology*. Vol. 3, ch 17.5, (Ed by D.J.Dermis; R.L.Dobson and J.McGuire). Harper & Row, Philadelphia.
- WATSON, K.C. & KALLICHURUM, K. (1970) Brain abscess due to Trichosporon cutaneum. *Journal of Medical Microbiology*, **3**, 191-193.
- YUNG, C.W., HANAUER, S.B., FRETZIN, D.S., RIPPON, J.W., SHAPIRO, C. & GONZALEZ, M. (1981) Disseminated Trichosporon beigeli. *Cancer*, **48**, 2107-2111.



This document is a scanned copy of a printed document. No warranty is given about the accuracy of the copy. Users should refer to the original published version of the material.